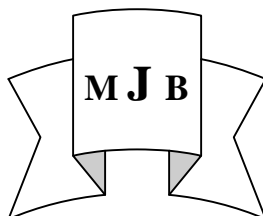


## In Spinal Metastases: Spinal Percussion is Profiling As Predictor and a Red Flag in Patients Present with Back Pain

Sabah J. AL-Rubiae

Dept. of Medicine . College of Medicine /University of Babylon, Hilla, Iraq.



### Abstract

**Back ground:** In patients with a history of systemic cancer(out side the spinal column) , presented with persistent back pain, the early detection and management of spinal metastases is of utmost important to help with pain control, prevent further spread and development of neurological complications.

**Objective:** To determine and evaluate the importance of spinal percussion, as a physical sign , and as evidence of spinal metastases.

**Methods:** A prospective study of 61 patients with a history of systemic cancer , presented with back pain and suspicion of spinal metastases, was carried out.

Full medical history and physical examination, including entire spinal percussion with a reflex hammer, were done for all patients.

All patients had ESR , serum alkaline phosphatase estimation and plain radiographic study of entire spine.

All patients had MRI scanning.

**Results:** The spinal percussion sign profiling as a red flag, carried a high sensitivity of 90% and specificity of 89.4% aiding in identifying the spinal metastases.

**Conclusions:** This test will help in prediction which patient with a history of primary cancer presented with back pain , have a high possibility of spinal metastases that need the priority , or at least to put them on the first line of waiting list of MRI for final diagnosis

### الخلاصة

ان اهمية الاكتشاف المبكر لانتشار المرض السرطاني الى العمود الفقري كمسبب لالام الظهر واعطاء العلاج اللازم له اهمية في تقليل الالم ومنع المضاعفات العصبية

تمت دراسة و متابعة 61 مريضاً مصاباً بمرض السرطان لاحد اعضاء الجسم ( خارج العمود الفقري) يعانون من الالم الظهر. تم اخذ التاريخ المرضي الكامل واجراء الفحص السريري، متضمناً فحص العمود الفقري بواسطة المطرقة الطبية. كذلك اجري فحص نسبة ترسيب الخلايا الحمراء ومستوى serum alkaline phosphatase. كذلك تم اخذ الصور الشعاعية للعمود الفقري بمنظرين امامي- خلفي وجانبي لجميع المرضى في الدراسة.

تم عمل فحص الرنين المغناطيسي للعمود الفقري لجميع مرضى الدراسة.

ان نتائج الدراسة بينت بان حساسية الفحص الطرقي للعمود الفقري هي ٩٠% ونوعيته ٨٩.٤% لذلك اعتبر هذا الفحص السريري من العوامل التنبؤية المهمة لاحتمالية عالية بوجود انتشار الورم السرطاني الى العمود الفقري مسبباً لالام الظهر.، ممكناً الطبيب المعالج باستبيان اكثر الحالات احتمالية يكون فيها الالم الظهر فيها بسبب انتشار الورم للعمود الفقري واعطاء هؤلاء المرضى، على الاقل، الاولوية في الدور لفحص الرنين المغناطيسي لكون هذا الفحص، أي الرنين المغناطيسي، محدد من حيث العدد ويأخذ وقتاً غير قصير لاجرائه في الوقت الحاضر.

### **Introduction**

**T**he spine is one of the most common sites of metastases[1]. Spinal metastases are the most frequently encountered spinal tumors and can effect up to 50% of cancer patients[2]. Batson's plexuses, a vertebral network of valve-less venous system, is one amongst main other routs of tumor spread which might allow malignant cells from internal organ to reach vertebral circulation in reverse direction during increase internal pressure as in coughing or sneezing[3-5] Both prevalence and incidence of metastasis are thought to be rising due to better early detection, and with appropriate treatment options of systemic malignancies resulting in increase patient's survival [2]. Although this serious condition, spinal metastases, are uncommon causes of back pain, its prevalence among primary care patient with back pain is less than 1% [6], they achieve clinical significance well out of proportion to their prevalence, as early diagnosis and treatment of spinal metastases is important to help with pain control, prevent further spread and development of other complications such as bladder and bowel dysfunction and cord compression[7]. In patients with a history of cancer presented with back pain, it often difficult to distinguish between both, the patients with spinal metastases and those with mechanical pain on clinical bases and plain radiograph. Even experienced physician are concerned with possibility of over looking this serious or life – threatening conditions [8]. The definitive and most sensitive diagnostic tool is Magnetic Resonance

Imaging( MRI) study<sup>3</sup>. However the access to MRI study is limited Therefore we need to improve our clinical suspicion through knowledge and considering most specific signs and symptoms of spinal metastases, which can result in proper selection of patients with highest possibility of spinal metastases for at least getting them in the line first for MRI scanning.

In our area we do not have enough data or studies about the significance and the importance of specific physical signs or red flags in identifying the underlying serious causes of back pain. This study aimed to elucidate the rule of spinal percussion, as a physical signs, in identifying of spinal metastases in patients with a history of systemic cancer presented with back pain.

### **Patients and Methods**

From May 2009 to March 2011 a sixty-one consecutive patients, (21) male and (40) female with a history of cancer presented with back pain were prospectively studied in rehabilitation and rheumatologic unit of Merjan teaching hospital .The diagnosis of the cancer were made according to the results of cytology and histopathological examinations. Exclusions criteria were: Pregnant females, patients with spinal primary tumors, contraindication to MRI, and a previous history of proved spinal metastases. A thorough history and physical examination were done. Spinal examination included inspection, flexion-extension, rotation palpation and gentle spinal percussion of the spinal processes of the thoracic and lumbar vertebrae with a reflex

hammer in prone position and the face of the patient was turned toward the examiner in order to recognize any emotional experience because of pain.

The clinical sign of percussion was considered positive when patient complains of sharp pain at one or multi levels on spinal percussion.

All patients denied a history of trauma and not responding to conservative treatment and had persistent back pain for more than four weeks durations .All the studied patients had no neurological deficit.

Plain radiograph of entire spine in two views anteroposterior and lateral were taken.

MRI was done for each patient mainly on the bases of history of cancer and according to persistency of pain. Erythrocyte sedimentation rate (ESR) using Westergren method, and because ESR generally increase with age and is somewhat higher in women .The upper limits of normal was measured as follow : For a man is equal to age divided by 2; for a woman add 10 to the age and divided by 2. Serum alkaline phosphates tests were done for each patient using photometric method and measured by international unit per liter I.U/L and the upper limits of normal is 85 I.U/L. The patients were informed about the study procedures and their consent were taken.

**Statistical analysis:** Descriptive analysis had been used. Results of measurements were presented as  $\pm$  SD, number and percentage (%).

Significance is assessed at 5% level of significance.

Sensitivity, specificity, positive predictive value and negative predictive value were used to determine the significant levels and the differences between groups. The

statistical software SPSS was used for data analysis.

## Results

All patients satisfying the criteria were completed the study. The mean age of patients was  $61.34 \pm 11.29$  years, ranging from 38-85 years with female/male ratio of 1.9

68.85% of patients(n=42) were found to have MRI evidence of secondary deposit with mean age of  $62 \pm 11.99$  years and with female ratio of 1.8. While 31.14% (n=19) of patients had no MRI evidence of spinal metastases and their mean age was  $60 \pm 10.06$  years. (p =0.505) with female/male ratio of 2.16

65.57% of patients (n= 40) were found to have positive spinal percussion sign in one or multiple spinal levels.

Of (40) patients with positive spinal percussion, (38) patients ( 95%) were found to have MRI in favor of secondary deposit.

Two patients with positive percussion sign were found to have negative MRI findings regarding possibilities of metastases. While (4) cases with a negative spinal percussion sign were found to have positive MRI findings regarding secondary deposit.

Recumbence or pain in supine position were found to be positive in 71.42% of patients (n=30) with spinal metastases evident by MRI scanning. Where as 52.63% of patients (n=10) without spinal metastases were found to have positive pain in supine position.

76.19% of patients (n=32) with spinal metastases were found to have night pain, compared with 68.42% of patients (n=13) without spinal metastases.

76.19% of patients (n=32) with spinal metastases were found to have age above 50 years. While 84.21% of

patients (n=16) without spinal metastases were found to have age above 50 years.

Only three cases of patients were found to have findings on plain radiograph suggesting of secondary spinal metastases which all then confirmed by MRI scanning.

Of 42 cases with spinal metastases 57.14% (n=24) were found to have elevated serum alkaline phosphates. Where as this enzyme was elevated in 57.89% (n=11) of patients without spinal metastases.

The mean ESR of all patients was  $49.13 \pm 14.4$  mm/1st hour.

The mean ESR of patients with spinal metastases was  $52.56 \pm 13.79$  mm/1st hour, while the mean ESR of patients without spinal metastases was  $43.04 \pm 14.04$  (p=0.012). The comparisons between profiles of patients with spinal metastases and those without are shown in table (1).

The sensitivity, specificity and predictive values of some of profiles of patients with spinal metastases and those without spinal metastases are plotted in table (2).

The regional distribution of MRI evident spinal metastases with corresponding positive spinal percussion test are shown in table (3).

**Table 1-** profile of patients with spinal metastases and patients without spinal metastases

	Patients with spinal metastases	Patients without spinal metastases
Mean age p.(0.505)	$62 \pm 11.99$	$60 \pm 10.06$
Female/male	1.8	2.16
Positive spinal percussion	38	2
Recumbence pain	30	10
Night pain	32	13
Age>50	32	16
Elevated SAP	24	11
X-ray findings Suggestive SM	3	0
Mean ESR p.(0.012)	$52.56 \pm 13.79$	$43.04 \pm 14.04$

SAP=Serum Alkaline Phosphates

SM=Spinal Metastases.

**Table 2** Shows the sensitivity and specificity , positive predictive value and negative predictive value of patients characters with and without SM

Character	patients with SM		patients without SM		Sensitivity	Specificity	PPV	NPP
	+ve	-ve	+ve	-ve				
Age>50	32	10	16	3	76%	15.7%	66.6%	23%
SP	38	4	2	17	90.4%	89.4%	95%	80%
RP	30	12	10	9	71%	47%	75%	42%
NP	32	10	13	6	76%	31.5%	71%	37.5%
S.A.P	24	18	11	8	57%	42%	68.5%	30.7%
X-ray findings Suggestive SM	3	39	0	19	7.1%	100%	100%	32%

SM= spinal metastases

PPV=positive predictive value

NPP=negative predictive value

SP= spinal percussion

RP= recumbence pain

NP= night pain

S.A.P=serum alkaline phosphates

**Table 3** shows the regional distribution of spinal metastases evident by MRI and number of corresponding positive spinal test.

Region	No. of MRI evident spinal metastases	No. of positive spinal percussion sign
Thoracic	24	23
Thoraco-lumbar	10	8
Lumbar	8	7
Total	42	38

### **Discussion**

This is one of first studies on importance of spinal percussion aiding in diagnosis of spinal metastases and their outcome from Babylon.

Malignancy or specifically speaking, spinal metastases is a diagnosis that practitioners would not wish to miss[9].

However early detection of the spinal metastases and with proper treatment options of primary tumor, can result in increase of patient survival and prevention of neurological deficit mainly due spinal cord compression [2, 7, 10]

On the data bases of this study, the mean age of the patients was >50 years, but there was no great differences between the mean ages of patients with negative MRI findings and those with spinal metastases as a cause of their back pain. (p.value=0.505).

A previous history of cancer is the red flag that raises the greatest index of suspicion to spinal metastases being the underlying cause of low back pain, but by how much is still unclear.[7,11]

The current study showed that 68.85 % (n= 42) of patients with low back pain and a history of cancer went on to have a diagnosis of spinal metastases as a cause of low back pain. In comparison to other studies this percentage is higher than that of Grant et.al 1991. who noted that about 10% of cancer patients will develop symptomatic spinal metastases [12] , and less than that of Hatrick et.al 2000, who stated that the vertebral column is the most common site of skeletal metastases , with up to 70-80% of cancer patients harboring secondary spinal metastases [13].

Amongst other red flags, the data of the current study showed that spinal

percussion test carried higher sensitivity in discrimination between both groups, patients with spinal metastases and patients without.

Moreover the other red flags, were found to be nearly identical between both the subjects with spinal metastases as a cause of low back pain and the subjects with mechanical back pain. Here the clinicians facing a challenge in screening for spinal metastases and they should refine the most important red flags. The current study was raising up the following important and relevant question: Which is more pertinent the quantity or the quality of red flags? Of course the quality is the answer. This fact was well evident in the current study when most of cases with spinal metastases associated with positive spinal percussion that profiling as higher red flag. While most of cases with mechanical back pain possessed two or more red flags, but lacking the positive spinal percussion test.

For this reason the current study was giving a weight to a spinal percussion as a red flag which increase the index of suspicion of spinal metastases as the underlying cause of back pain.

Unfortunately there were not enough studies to compare with, however in comparison to James et al study 2010, who used the closed- fist in spinal percussion to detect the pain due under lying osteoporotic vertebral fractures , that carried a sensitivity of 87.5% and specificity of 90% [14] versus sensitivity of 90% and specificity of 89.4% of the current study, showing that no great differences between two studies, although the sensitivity is a little bit higher in the current study.

Closed-fist spinal percussion sensitivity in thoracic spine was more

than lumbar spine. This might be due to muscular thickness in lumbar region as the author postulated [14]. where as in the current study the sensitivity of spinal percussion by a reflex hammer are the same both in thoracic and lumbar region, because the percussion force will hit precisely the spinal processes and transmitted through arches to vertebral bodies. For that reason, percussion of spinal processes with a reflex hammer may aid in differentiating pain from the vertebral column versus deeper retroperitoneal structures [15]. Generally, pain with percussion suggest spinal pathology such as infection, fractures [15]. In study of Chandrasekar et al 1990 showed that, tenderness to spinal percussion had 86% sensitivity for bacterial infection, but was only 60% specific [16].

According to the specificity and sensitivity of serum alkaline tests in the current study, it considered as a poor predictive value for suspicion of spinal metastases presenting as back pain. This finding is consistent with study of Martin et al 2004. [17]

The current study showed that a difference in the means of ESR of both groups ( $p$ -value =0.012) and Plain radiographic study showed very low sensitivity despite these (ESR and plain radiography) being useful screening tools [11,18], but they are not always sensitive to pick up spinal pathology [7]. Although plain radiograph may easily available, but, unfortunately, spinal tumor cannot be well visualized on radiograph until significant destruction occurred [1, 19].

Lytic bone lesion must be greater than 1cm and have destroyed 30-50% of the bone density, in order to be seen by plain radiograph [3,8]

Moreover plain radiograph in most cases and are a common source of over diagnosis of osteoarthritic or spondylotic conditions [10, 19, 20]. However, the MRI scan of whole spine is considered the gold standard for detection or ruling out of spinal neoplasia [7, 8]. But unfortunately the accesses to MRI are limited for present time and it is need for patients to wait several weeks if not months to get this scan.

### **Conclusion**

Among red flags, the spinal percussion test carried a high sensitivity and specificity. This a physical sign-related red flag greatly increase the index of suspicion for spinal metastases as a potential underlying cause of back pain in patient with a history of cancer. Although spine MRI is currently the powerful and definite available diagnostic tool in identification of spinal metastases, but it is of limited resource and accesses in our area for present time. Therefore the spinal percussion sign is useful as a predictor and will help in discrimination of patients with highest risk of spinal metastases in order to put them, at least, on the first line or on top of waiting list of MRI scanning.

### **References**

- 1-Krzysztof Siemionow, Michael Steinmetz, Gordon Bell, Hakan Ilaslan, Robert F. McLain: Identifying serious causes of back pain: Cancer, infection, fracture : review article Cleveland Clinic Journal of Medicine . 2008;75(8): p.557- 566.
- 2-Ran Harel , Lilyana Angeoly: Spine metastases: Current treatments and future detections. Eurp. J of Cancer Oct 2010;46,(15): p 2696-2707.

- 3-Henry :Metastatic Tumors In Bone-Introduction: Available at <http://www.bonetumor.org/metastatic-tumors-bone-introduction> 8 Sept. 2009
- 4-Harms: Bone Metastases: Available at: <http://www.google.iq/search?q=Harms%3A+Bone+Metastases%3A&btnG=%D8%A8%D8%AD%D8%AB&hl=ar&lr=&spell=1&sa=X&aq=f&aqi=&aql=&oq> 2007
- 5-Natalia Lshchyna, Shawn Henderson: Acute onset- low back pain and hip pain secondary to metastatic prostate cancer: a case report J Can Chiropr Assoc 2004 ; 48 (1): 5-12
- 6-Deyo RA, Dohl: Cncer as a cause of low back pain: Frequency, clinical presentation and diagnostic strategies. Journal of Gen Intern Med 1988;1: 20-25 .
- 7-Eden Keillar: Cancer as a Cause of Low Back Pain. available at: March 2009
- 8-Krzysztof Siemionow, Robert F. McInain: When back pain is not benign Post Graduate Medicine 2006;119(2)
- 9-Martin Underwood: Diagnosing Acute Non specific Low Back Pain: Time to Lower Red Flags? Arthritis and Rheumatism Oct. 2009;60(10): pp 2855-2857.
- 10-George E.M. Kienstra, Caroline B.Terwee, Friedo W Dekker, Leo R.Canta, Aernout C.W.Borstlap, Cees C.Tijssen, Andries Bosch, Jan G.P.Tijssen: Prediction of Spinal Epidural Metastases. Arch. Neurol. 2000;57:690-695.
- 11-Henschke N, Maher CG, Refshauge KM: Screening for Malignancy in Low Back Pain Patients: a systemic review. European Spine Journal 2007; 16:1673-1679.
- 12-Grant R, Papadopoulos SM, Greenberg HS: Metastatic epidural spinal cord compression. Neurol Clin 1991;9:825-841.
- 13-Hatrick NC, Lucas JD, Timothy AR, et al: The surgical treatment of metastatic disease of the spine Radiother Oncol 2000;56:335-339
- 14-James Langdon, Adam Way, Samuel Heaton, Jason Bernard, Sean Molloy: Vertebral compression fractures- New clinical signs to aid diagnosis. Ann R Coll Surg Engl 2010;92:163-166.
- 15- Simon. Chapter -7 approach to neck and back pain : available at:<http://www.google.iq/search?q=simon-chapter-7-approach-to-neck-and-back-pain.pdf&btnG=%D8%A8%D8%AD%D8%AB&hl=ar&lr=&spell=1> Aug.30, 2010
- 16-Chandrasekar PH. Low-back pain and intravenous drug abusers Arch Intern Med. 1990;150(5):1125-1128
- 17-Martin Hetzel, Juergen Hetzel, Coskun Arsalanemir, Karin Nussle, Holger Schrmmeister. Reliability of symptoms to determine use of bone scan to identify bone metastases in lung cancer: prospective study. BMJ 2004;328: 1051-1052 .
- 18- Joines JD, McNutt RA, Carey TS, et al. Finding cancer in primary care out patient with low back pain: A comparison of diagnostic studies. J Gen Intern Med 2001 16: 14-23
- 19- Spinal Problems: available at: <http://www.ucl.ac.uk/~regfjxe/SPINAL.htm>
- 20-Van den Bosch MAAJ, Hollingworth W, Kinmonth AL, Dixon AK. Evidence against the use of lumbar spine radiography for low back pain. Clin Radiol 2004;59:69-76